

Network localization of hemichorea-hemiballismus

Simon Laganieri, MD
Aaron D. Boes, MD, PhD
Michael D. Fox, MD,
PhD

Correspondence to
Dr. Laganieri:
slaganie@bidmc.harvard.edu
or Dr. Fox:
foxmdphd@gmail.com

ABSTRACT

Objective: To determine whether neuroanatomically heterogeneous strokes causing hemichorea-hemiballismus localize to a common functional network.

Methods: We identified 29 cases of lesion-induced hemichorea-hemiballismus from the literature and mapped each lesion volume onto a reference brain. Using a recently validated technique termed lesion network mapping, we tested whether these lesions belonged to the same functional network. To accomplish this, the network of brain regions functionally connected to each lesion was identified using a connectome dataset from healthy participants. Network maps were overlapped to identify any region functionally connected to our set of lesions. Specificity was evaluated using a case-control design; control cohorts included a group of similar lesions randomized to different brain locations and a second group of lesions causing a separate movement disorder, asterixis. Reproducibility was evaluated using an independent cohort of 10 additional hemichorea-hemiballismus cases.

Results: Lesions showed heterogeneity in anatomical location, consistent with prior reports. However, at least 90% of these lesions showed network overlap in the posterolateral putamen. This result was specific to lesions causing hemichorea-hemiballismus and reproducible in an independent cohort. The putaminal overlap site was itself connected to a broader motor network that predicted the distribution of lesions causing hemichorea-hemiballismus.

Conclusions: Strokes causing hemichorea-hemiballismus, while anatomically heterogeneous, localize to a common functional network. Specifically, lesions occur in regions functionally connected to the posterolateral putamen, a region previously implicated in hyperkinetic movement disorders. Lesion network mapping may be useful in identifying the neuroanatomical substrates of heterogeneous lesion-based disorders. *Neurology*® 2016;86:2187-2195

GLOSSARY

rs-fcMRI = resting-state functional connectivity MRI; **STN** = subthalamic nuclei.

Lesion mapping relates the location of focal brain lesions to resulting neurologic symptoms, and has helped identify anatomical correlates of language, memory, attention, and many other functions.¹ Despite these successes, a select number of syndromes have proven elusive to standard lesion mapping approaches. A canonical example is stroke-induced hemichorea-hemiballismus, a syndrome consisting of 2 movement disorders that typically coexist² and together comprise the most frequently reported poststroke movement disorder.³⁻⁵

Classic teaching in neurology⁶ and landmark studies in humans⁷ and nonhuman primates⁸ highlight the role of lesions to the contralateral subthalamic nuclei (STN) in producing hemichorea-hemiballismus. However, causative lesions have been reported in the cortex, caudate, putamen, thalamus, and brainstem⁹⁻¹¹ and strokes directly affecting the STN constitute a minority (10%–30%) of cases.^{5,9,12} Such findings have led to the hypothesis that the locus of pathology in hemichorea-hemiballismus resides in the disruption of a common distributed

Supplemental data
at Neurology.org

From the Berenson-Allen Center for Noninvasive Brain Stimulation (S.L., A.D.B., M.D.F.), Division of Cognitive Neurology, Department of Neurology, Harvard Medical School and Beth Israel Deaconess Medical Center, Boston; Departments of Pediatric Neurology (A.D.B.) and Neurology (M.D.F.), Massachusetts General Hospital, Harvard Medical School, Boston; Athinoula A. Martinos Center for Biomedical Imaging (M.D.F.), Massachusetts General Hospital, Charlestown.

Go to Neurology.org for full disclosures. Funding information and disclosures deemed relevant by the authors, if any, are provided at the end of the article.

motor network rather than a single anatomical site.^{5,12–14} However, evidence linking these heterogeneous lesion locations to a specific network is lacking.

A recently validated technique termed lesion network mapping¹⁵ is particularly well-suited to address this hypothesis. This technique uses normative connectome data to identify the networks associated with focal brain lesions, including historical lesions from the literature, without the need for specialized imaging of affected patients.¹⁵ In this article, we use lesion network mapping to test the hypothesis that lesions causing hemichorea-hemiballismus demonstrate functional connectivity to a common brain network.

METHODS Case selection. Cases of stroke-induced hemichorea-hemiballismus were identified through a literature search designed to identify a representative, but not necessarily comprehensive, cohort. Using pubmed.org, we searched for the combined terms hemichorea, hemiballismus, and stroke. The search, performed in August 2014, was limited to articles in English available electronically through full text links. Inclusion criteria included (1) examination documenting either hemichorea, defined as unilateral rapid involuntary movements with flexion and extension, rotation, or crossing, which may involve all body parts, predominantly distal,⁶ or hemiballismus, defined as a severe involuntary, arrhythmic, explosive, large-amplitude excursion of a limb at proximal joints⁶; (2) acute onset hemichorea-hemiballismus secondary to stroke; and (3) ischemic or hemorrhagic lesions displayed in the article. Exclusion criteria included extrinsic compression injuries, significant mass effects, presence of competing etiologies for hemichorea-hemiballismus (e.g., hyperglycemia-induced hemichorea), or poor image resolution. Twenty-nine cases were identified using these criteria.

Lesion mapping. Lesion location, as displayed in figure 1, was manually traced onto a reference brain (MNI152 brain, 2 × 2 mm; <http://fsl.fmrib.ox.ac.uk/fsldownloads>) using FSL. Neuroanatomical landmarks were used to ensure accurate transfer onto the template. In cases where multiple lesions were displayed, lesions were combined into a single volume. All lesions were mapped true to their laterality. The initial cohort of 29 lesions is displayed in figure 1.

Lesion network mapping. To investigate the networks associated with hemichorea-hemiballismus lesions, we applied a validated technique termed lesion network mapping¹⁵ (figure 2). This technique involved 3 steps: (1) the volume of each lesion was transferred to a reference brain; (2) the network of brain regions functionally connected to each lesion was computed using resting-state functional connectivity MRI (rs-fcMRI) data from a large cohort of normal participants; and (3) the resulting lesion network maps were thresholded and overlaid to identify common network sites across the lesions. Lesion network mapping has been validated across 4 different syndromes (visual hallucinations, auditory hallucinations, pain, and aphasia), in each case linking heterogeneous lesions to specific sites known to be involved in symptom expression.¹⁵

Our normative rs-fcMRI dataset consisted of 98 healthy participants (48 male, ages 22 ± 3.2 years), part of a publicly available dataset.¹⁶ Full methodologic details for this dataset are available (e-Methods on the *Neurology*[®] Web site at Neurology.org).^{17,18}

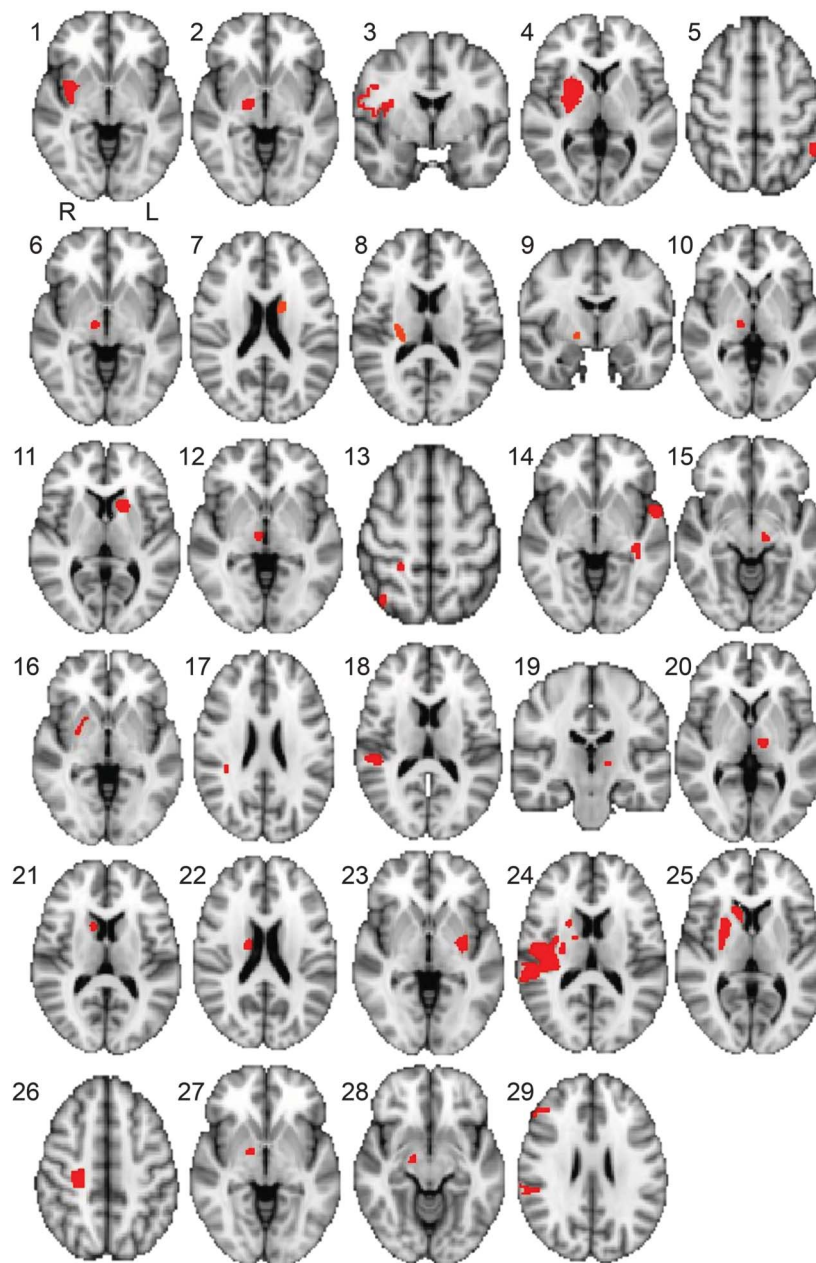
Rs-fcMRI maps were created for each lesion using a standard seed-based approach. Specifically, the time course of the blood oxygen level-dependent signal within the lesion volume was extracted for each participant in the normative cohort. Correlations between this extracted signal and all other brain voxels were identified and results were combined across participants using a *t* test. Each of the 29 individual lesion-seeded rs-fcMRI network maps was thresholded at a *t* value of positive or negative 4.25 (*p* < 0.00005, uncorrected), as performed previously.¹⁷ After applying this threshold, resulting network maps were binarized and overlapped to identify regions of shared positive or negative correlation. A threshold for the group analysis was set at 85% (25 of the 29 cases).

Specificity. To evaluate the specificity of our findings, we performed 2 control analyses. First, to ensure that the results were specific to hemichorea-hemiballismus lesions and not the result of any set of similarly sized but randomly distributed lesions, we repeated the analysis with the same 29 lesions in terms of volume, but randomized to anywhere in the brain (except the cerebellum, where no hemichorea-hemiballismus lesions were found). Ten iterations of the lesion randomization process generated 10 separate randomized control groups, each with 29 randomized lesions, for a total of 290 randomized lesions. The lesion randomization process controlled for the maximum degree of lesion overlap and interlesion distances by excluding iterations that differed from the values obtained for the hemichorea-hemiballismus lesions. The randomly generated lesion volumes were converted to a cube with automated morphing of the shape as needed to ensure that all voxels fell within the brain.

Second, to control for the possibility that our findings might have been obtained with any set of strokes resulting in abnormal movements, we generated another control group of 30 cases of stroke-induced asterixis.¹⁹ We chose this comparison cohort as it is the second most common stroke-induced movement disorder,^{6,19} has a similar acute onset,¹¹ and was readily available in the literature.¹⁹ Asterixis cases included 30 patients, 18 men, ages 47–83, mean 66 years. There were 22 ischemic infarcts and 8 hemorrhages. Lesion locations included thalamus, cortex, brainstem, and cerebellum. Asterixis occurred unilaterally in 26 and bilaterally in 4, with contralateral symptoms in all cases except for 2 cerebellar lesions, where symptoms were ipsilateral. None of these reported symptoms of hemichorea-hemiballismus.¹⁹

Two separate voxel-wise statistical approaches were used to compare results obtained using our initial hemichorea-hemiballismus cohort to the 2 control cohorts. First, a voxel-wise Lieberman test was used to generate a z-score map, which reflected the strength of the association of each voxel to the hemichorea-hemiballismus networks relative to control networks. This statistical approach has been described previously.²⁰ The Lieberman test requires voxels to be classified in a binary fashion (lesioned or not) and can be insensitive to nonlinear relationships between lesion and behavior.¹ To avoid this limitation, we repeated each comparison using a voxel-wise 2-tailed *t* test, thereby capturing the strength of the network at each voxel as a continuous variable. Results of both voxel-wise analyses were masked to the putamen as this was the only site to show consistent connectivity to hemichorea-hemiballismus lesions.

Figure 1 Lesion locations



Lesion location of 29 cases of stroke-induced hemichorea-hemiballismus in cross-section, manually traced onto a reference brain. All lesions were traced true to their laterality, right/left orientation for each lesion as shown on the upper left cross-section.

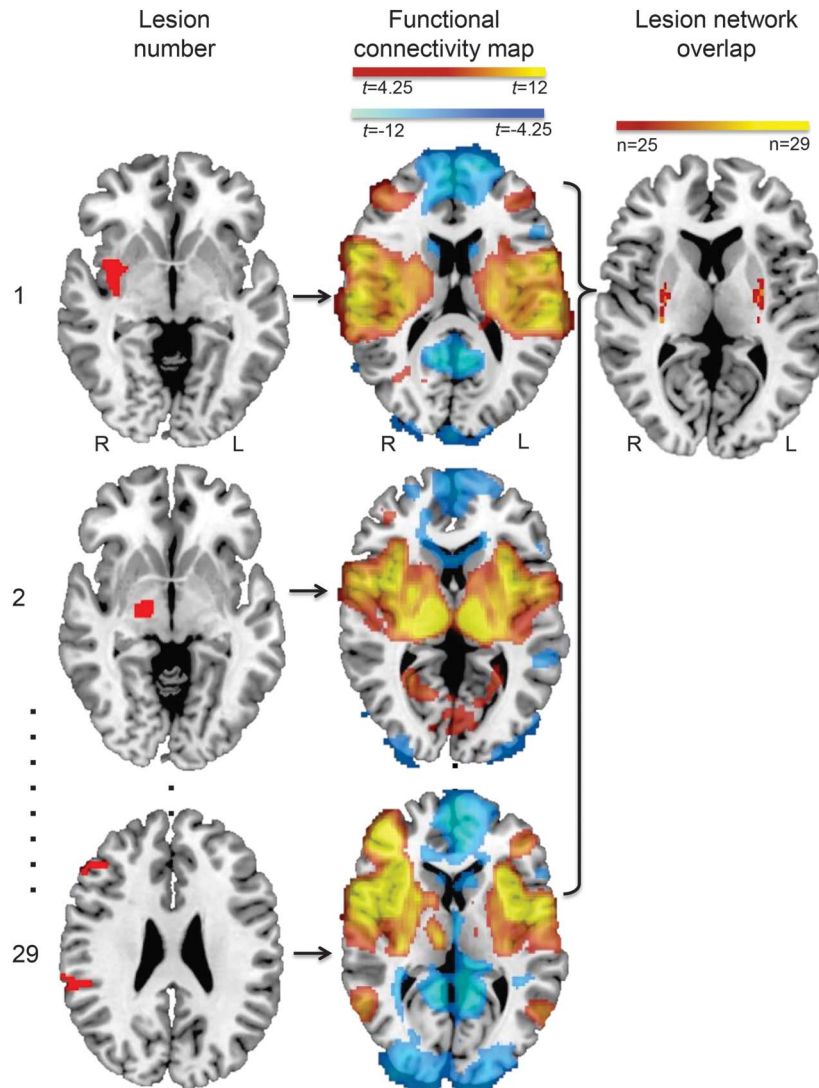
Reproducibility. A secondary replication cohort of hemichorea-hemiballismus lesions was generated post hoc by expanding the search criteria (dropping the requirement for full text links) and adding unpublished cases from neurologists at our institution. The replication cohort consisted of 10 cases, 8 from the literature and 2 from our institution (table e-1B). Lesion network mapping was repeated; peak network overlap within the posterolateral putamen was computed and compared to asterixis lesions using a χ^2 test.

Functional connectivity of the region of maximum overlap. To investigate areas functionally connected to the site of maximal overlap, we thresholded the network overlap image at the maximal overlap (26/29 or 90%) and used this region of interest

to generate a subsequent rs-fcMRI network map. Peak coordinates were identified using a cluster analysis with a threshold of $t = 9$ (positive correlation only) and minimal cluster size of 5 voxels. The map was displayed on a template brain using FSL and on the cortical surface using CARET.²¹ To demonstrate that this map contained the locations of causative lesions, it was overlapped with 10 lesions from our validation cohort.

Retrospective analysis of lesion cases. Network maps generated for 3 of our initial 29 lesions (5, 13, and 26) did not show strong connectivity to the voxels of maximal network overlap. To better understand these exception cases, network maps were reexamined. Lesions containing multiple separate foci were split into isolated seeds to generate separate rs-fcMRI network maps.

Figure 2 Lesion network mapping technique



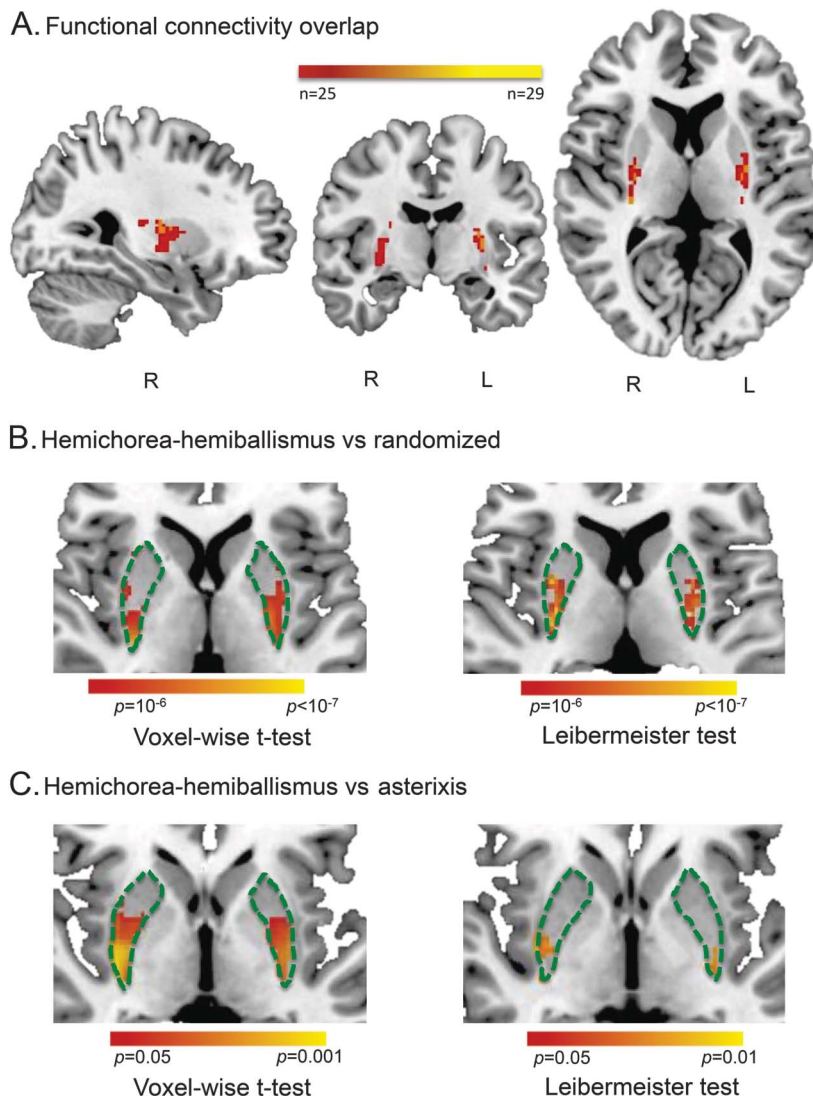
Stroke locations were manually traced onto template brain to create 29 separate brain volumes (left). Functional connectivity maps for each lesion volume were then derived from a large dataset of healthy controls (middle). The 29 functional connectivity maps were then overlapped to identify common networks across the lesions (right). Small black dots between maps 2 and 29 symbolize that each lesion in the cohort was processed in the same fashion to generate intermediate maps.

RESULTS Our initial search identified 29 cases of hemichorea-hemiballismus (figure 1). Ages ranged from 34 to 81 (mean 60.2) years. Lesions were anatomically heterogeneous with primary locations in cortex (8), STN (8), putamen (6), caudate (5), midbrain (1), and subcortical white matter (1). Eight lesions were in the left hemisphere and 21 lesions in the right. No lesions involved the cerebellum. Five strokes were hemorrhagic and 24 were ischemic. In 18/29 cases, hemichorea-hemiballismus persisted for less than 6 months, consistent with large retrospective studies.⁵ Hemichorea-hemiballismus was always contralateral to the side of the lesion.

Next, the network associated with each lesion location was computed and areas of network overlap identified (figure 2). Despite marked heterogeneity in

lesion location, overlap of lesion-derived networks was high (90%), and occurred specifically within the bilateral posterolateral putamen (figure 3A). No other areas of network overlap (positive or negative) met our threshold (>85% overlap). We contrasted these results with those from similarly sized lesions randomized to different locations (figure 3B) and a group of lesions causing asterixis (figure 3C). The posterolateral putamen showed significantly higher connectivity to lesions causing hemichorea-hemiballismus than either of these control cohorts, using either a voxel-wise *t* test or Lieberman test.

In the asterixis control group, maximum network overlap was 22/30 lesions (73%), and unlike hemichorea-hemiballismus, this overlap occurred in the thalamus (figure e-1).



Overlap of lesion network maps from hemichorea-hemiballismus lesions show peak overlap (26/29) in the posterolateral putamen (A). Overlap in this area was significantly greater than that seen with randomized lesions (B) or lesions causing asterixis (C) using 2 different statistical approaches (voxel-wise t test or voxel-wise Leibermeister test). Specificity analyses were masked to the putamen and thresholded to demonstrate voxels with peak p values.

Our expanded search criteria identified 10 additional cases of hemichorea-hemiballismus, 8 from the literature and 2 from our institution. Ages ranged from 21 to 82 (mean 62.2) years. Lesions were once again heterogeneous with locations primarily in STN (3), subcortical white matter (3), caudate (2), cortex (1), and thalamus (1). Six lesions were right-sided, 4 were left-sided. One case was hemorrhagic and the rest were ischemic. In 9/10 cases, hemichorea-hemiballismus was contralateral to the lesion; in one case it was ipsilateral.

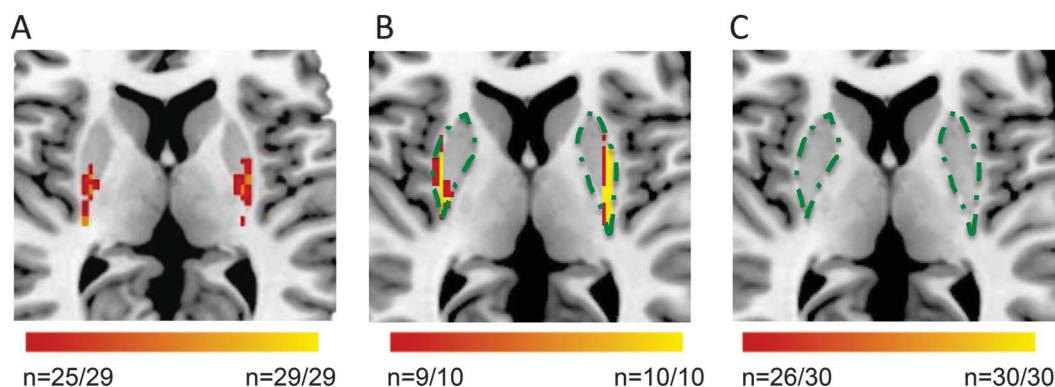
In this replication cohort, 10/10 lesions showed network overlap in the posterolateral putamen (figure 4). Applying this same analysis to asterixis lesions revealed no overlap in this area (figure 4). Peak network overlap within the posterolateral putamen was

significantly different between the replication and asterixis cohorts ($p < 0.05$, χ^2).

Given the historical focus on the STN, we specifically examined network overlap in this area. Peak overlap was 24/29 (83%) for the initial cohort, 7/10 (70%) in the replication cohort, and 21/30 (70%) in the asterixis cohort. The difference in peak overlap between the hemichorea-hemiballismus cohort and the asterixis cohort was not significant within the STN ($p > 0.05$, χ^2).

Although network overlap in the posterolateral putamen was high for hemichorea-hemiballismus lesions (36 of 39 across both cohorts), 3 lesions failed to show functional connectivity to this site (lesions 5, 13, and 26, figure 1, table e-1A). One of these (lesion 26) actually did show functional connectivity to the posterolateral

Figure 4 Reproducibility of results in a second independent cohort



(A) Lesion network mapping of an initial cohort of 29 cases of stroke-induced hemichorea-hemiballismus shows peak network overlap in the posterolateral putamen. (B) Lesion network mapping of a validation cohort of 10 additional cases of hemichorea-hemiballismus shows network overlap within the same area. (C) Lesion network overlap of 30 cases of asterix demonstrates absence of network overlap within the posterolateral putamen.

putamen, but to voxels slightly adjacent to the voxels of maximal overlap (figure e-2A; reproduced with permission from Springer Science+Business Media: Chung et al. *Hemichorea after stroke: clinical-radiological correlation*. *J Neurol* 2004;251:725–729).⁹ Lesion 13 was composed of 2 separate lesions. When run independently, 1 lesion showed significant connectivity to the posterolateral putamen (figure e-2B). Finally, although lesion 5 was reported as a solitary lesion,⁹ inspection of the published image (figure e-2C) suggested the presence of additional smaller lesions. These smaller lesions showed strong connectivity to the posterolateral putamen (figure e-2C).

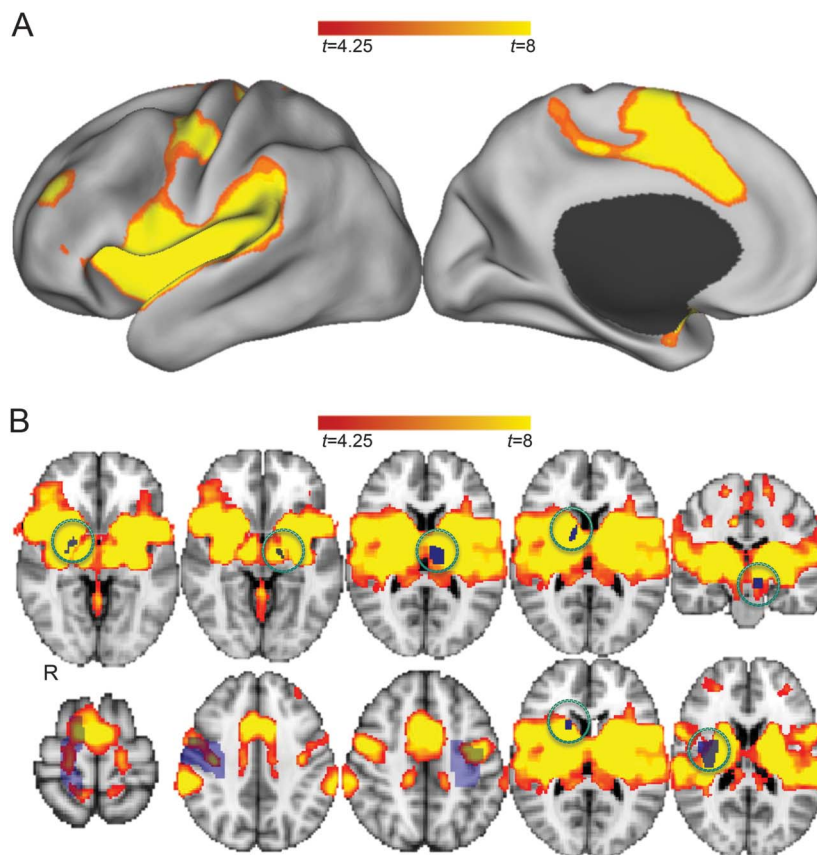
Given the emphasis our results placed on the posterolateral putamen, we further evaluated the connectivity of this site to the rest of the brain. We computed functional connectivity between our site of maximal network overlap in the posterolateral putamen (from our initial cohort) and all other brain voxels (figure 5). We found significant connectivity to several regions implicated in motor control, including the left putamen (Montreal Neurological Institute coordinates: $x = -30$, $y = -8$, $z = 8$), supplementary motor area (4, -2, 58), right motor/premotor cortex (48, -4, 48), and left motor/premotor cortex (-36, -14, 40). Notably, this network overlapped with the location of all independent lesions in our replication cohort (figure 5B).

DISCUSSION Here we show that strokes causing hemichorea-hemiballismus, despite being heterogeneous in their anatomical localization, are located within a single network with shared functional connectivity to the posterolateral putamen. This finding has potential implications for understanding the pathophysiology of hemichorea-hemiballismus, the utility of lesion network mapping, and the identification of therapeutic targets.

Historically, lesion-induced hemichorea-hemiballismus appeared to result, in all cases, from a focal disruption of the corpus luyisii/STN.⁷ Findings such as these were incorporated into the classic model of basal ganglia circuitry, which suggested that hyperkinetic movement disorders, such as hemichorea-hemiballismus, occurred through disinhibition of the thalamus and increased cortical excitation.^{12,22} Although this framework provided a mechanism for the effect of STN strokes, it did not readily account for lesions in many alternate locations.¹² Further, predictions made by this model, such as decreased inhibition in the primary motor cortex, have not always been supported experimentally.²³ Although this model continues to expand,²⁴ the link between hemichorea-hemiballismus-inducing strokes in remote locations to known motor pathways has remained elusive. These findings have led to the hypothesis that motor pathways involved in hemichorea-hemiballismus are likely to be complex and widely distributed throughout the brain.^{5,6,13} Our results support this view and implicate a network centered on the posterolateral putamen, a region functionally connected to several important nodes in the motor network including motor cortex, premotor cortex, supplementary motor area, and STN.

The present findings are consistent with results from other nonstroke causes of this phenotype. For example, hemichorea-hemiballismus from nonketotic hyperglycemia consistently shows abnormalities in the putamen.²⁵ Chorea in Huntington disease is associated with putaminal atrophy²⁶ and several primate models of Huntington chorea have been generated by lesioning the bilateral putamen.²⁷ Other causes of hemichorea with abnormalities specifically within the putamen include Lesch-Nyhan disease,²⁸ Wilson disease,²⁹ and neuroacanthocytosis.³⁰ In one reported case, hemichorea-hemiballismus resolved

Figure 5 Resting-state functional connectivity with the site of maximal network overlap in the bilateral posterior putamen



Results are displayed on the cortical surface (A) and in volume space (B). Regions functionally connected to the posterolateral putamen include bilateral supplementary motor area and bilateral motor/premotor cortex. Superimposed on the network map in volume space (B) are the 10 lesions from the hemichorea-hemiballismus validation cohort (in purple, smaller lesions circled in green).

after microsurgical resection of a vascular malformation in the putamen.³¹

Given the historical emphasis on the STN, its causal relationship in numerous pathologically confirmed cases, and the inclusion of several STN lesions in our own analysis, it is interesting that this structure did not emerge as the site of maximal overlap. In both the initial and validation cohorts, network overlap within the STN did not reach our threshold criteria of 85%. However, the STN does emerge at lower thresholds and is strongly functionally connected to the site of maximal network overlap in the posterolateral putamen, suggesting that it probably constitutes an important node in a more broadly distributed network.

The present results go far towards establishing a factor necessary for the emergence of poststroke hemichorea-hemiballismus: 36 of 39 lesions showed connectivity to the posterolateral putamen and the remaining 3 lesions showed connectivity in post hoc analyses. These findings also demonstrate a degree of specificity as hemichorea-hemiballismus lesions were more strongly connected to the posterolateral

putamen than similar lesions randomized to other locations or lesions causing asterixis. However, connectivity to the posterolateral putamen should not be interpreted as sufficient to cause lesion-induced hemichorea-hemiballismus. As one example, poststroke dystonia without hemichorea-hemiballismus has been reported following lesions to the posterior putamen.³² Similarly, one would expect pure motor strokes to show connectivity to the motor/posterolateral putamen. As such, additional factors including a relatively intact corticospinal tract may be required. Full investigation into these other factors is another important topic for future work.

The finding that hemichorea-hemiballismus lesions fail to localize to a single region, but share connectivity to a single region, is consistent with recent results from several other stroke syndromes.¹⁵ The current article goes beyond this prior work by investigating a new syndrome, hemichorea-hemiballismus, in which there was no clear a priori hypothesis regarding the exact network location. Further, this study is novel in demonstrating network overlap in a subcortical region and in using a replication cohort to

validate the findings obtained from lesion network mapping. The fact that the posterolateral putamen occupies a central anatomical and functional role within the basal ganglia–thalamocortical motor loop^{33–35} and is implicated in other causes of hemichorea-hemiballismus supports our results and suggests that lesion network mapping may be useful in other syndromes with unknown localization.

There are several limitations to the present work. First, this technique does not explain how remote stroke-induced disruptions exert their pathophysiological influence. Second, most lesions were obtained from published 2D figures. Thus, the analysis could not account for the potential contributions of chronic lesions or lesions that were not highlighted in the article. Fortunately, prior validation studies comparing 2D representations to actual 3D lesions showed nearly identical results when using lesion network mapping.¹⁵ Further, we were able to identify 2 local cases in which the full 3D volume could be traced and the possibility of additional chronic lesions excluded. Third, our technique does not account for downstream compensatory or reactionary changes to focal disruptions, which may be important mediators of hemichorea-hemiballismus. Finally, for most cases, we relied on published clinical descriptions potentially leading to diagnostic inaccuracy or heterogeneity. However, such variability should bias us against the present findings.

The current article uses a recently validated method, lesion network mapping, to link anatomically heterogeneous lesions causing hemichorea-hemiballismus to a single functional network of motor regions. In doing so, we highlight the importance of the posterolateral putamen in the pathophysiology of lesion-induced hemichorea-hemiballismus. Testable hypotheses based on these findings include the prediction that function within the posterolateral putamen should be abnormal in patients with stroke-induced hemichorea-hemiballismus if studied with imaging sensitive to such changes. Further, neuromodulation aimed at the posterolateral putamen or its associated network may represent a promising therapy in symptomatic patients.³⁶ To this end, it is worth noting that transcranial magnetic stimulation applied to the SMA, a cortical node in this network, has shown some promise for improving chorea.³⁷

AUTHOR CONTRIBUTIONS

S.E.L. performed the analyses and wrote the manuscript. A.D.B. helped with image processing methodology, edited the manuscript, and contributed important ideas to the final product. M.D.F. oversaw the project and helped S.E.L. with data analysis and writing the manuscript.

STUDY FUNDING

S.E.L. was supported by a fellowship grant from the Sidney R. Baer Jr. research foundation. A.D.B. was supported by NIH/National Institute

of Neurological Disorders and Stroke grant 5R25NS065743-05. M.D.F. was supported by NIH grant K23NS083741, by the Dystonia Medical Research Foundation and by the National Parkinson Foundation. Work on this study was also supported by grants from the NIH and National Center for Research Resources: Harvard Clinical and Translational Science Center (UL1 RR025758).

DISCLOSURE

S. Laganieri and A. Boes report no disclosures relevant to the manuscript. M. Fox is listed as an inventor on submitted patent applications using fMRI to guide brain stimulation. Go to Neurology.org for full disclosures.

Received September 22, 2015. Accepted in final form March 4, 2016.

REFERENCES

1. Geva S, Baron JC, Jones PS, et al. A comparison of VLSM and VBM in a cohort of patients with post-stroke aphasia. *Neuroimage Clin* 2012;1:37–47.
2. Kase CS, Maulsby GO, deJuan E, Mohr JP. Hemichorea-hemiballismus and lacunar infarction in the basal ganglia. *Neurology* 1981;31:452–455.
3. Huang HC, Wu YC, Shih LY, Lo WC, Tsai CH, Shyu WC. Reversible abnormal functional neuroimaging presentations in polycythemia vera with chorea. *J Neurol* 2011;258:2054–2057.
4. Alarcon F. Post-stroke movement disorders: report of 56 patients. *J Neurol Neurosurg Psychiatry* 2004;75:1568–1574.
5. Ghika-Schmid F, Ghika J, Regli F, Bogousslavsky J. Hyperkinetic movement disorders during and after acute stroke: the Lausanne Stroke Registry. *J Neurol Sci* 1997;146:109–116.
6. Caplan LR, van Gijn J. *Stroke Syndromes*. 3rd ed. Cambridge: Cambridge University Press; 2012.
7. Martin JP. Hemichorea resulting from a local lesion of the brain (the syndrome of the body of Luys). *Brain* 1927;50:637–649.
8. Whittier JR, Mettler FA. Studies on the subthalamus of the rhesus monkey; hyperkinesia and other physiologic effects of subthalamic lesions; with special reference to the subthalamic nucleus of Luys. *J Comp Neurol* 1949;90:319–372.
9. Chung S, Im J-H, Lee M, Kim J. Hemichorea after stroke: clinical-radiological correlation. *J Neurol* 2004;251:725–729.
10. Kawamura M, Takahashi N, Hirayama K. Hemichorea and its denial in a case of caudate infarction diagnosed by magnetic resonance imaging. *J Neurol Neurosurg Psychiatry* 1988;51:590–591.
11. Ghika J. Movement disorders in stroke [in French]. *Rev Neurol* 2008;164:833–836.
12. Postuma RB, Lang AE. Hemiballismus: revisiting a classic disorder. *Lancet Neurol* 2003;2:661–668.
13. Schwarz GA, Barrows LJ. Hemiballismus without involvement of Luys' body. *Arch Neurol* 1960;2:420–434.
14. Handley A, Medcalf P, Hellier K, Dutta D. Movement disorders after stroke. *Age Ageing* 2008;38:260–266.
15. Boes AD, Prasad S, Liu H, et al. Network localization of neurological symptoms from focal brain lesions. *Brain* 2015;138:3061–3075.
16. Holmes AJ, Hollinshead MO, O'Keefe TM, et al. Brain Genomics Superstruct Project initial data release with structural, functional, and behavioral measures. *Sci Data* 2015;2:150031.
17. Fox MD, Buckner RL, White MP, et al. Efficacy of transcranial magnetic stimulation targets for depression is

- related to intrinsic functional connectivity with the subgenual cingulate. *Biol Psychiatry* 2012;72:595–603.
18. Fox MD, Halko MA, Eldaief MC, Pascual-Leone A. Measuring and manipulating brain connectivity with resting state functional connectivity magnetic resonance imaging (fcMRI) and transcranial magnetic stimulation (TMS). *Neuroimage* 2012;62:2232–2243.
 19. Kim JS. Asterixis after unilateral stroke: lesion location of 30 patients. *Neurology* 2001;56:533–536.
 20. Rorden C, Karnath H-O, Bonilha L. Improving lesion-symptom mapping. *J Cogn Neurosci* 2007;19:1081–1088.
 21. Van Essen DC, Drury HA, Dickson J, et al. An integrated software suite for surface-based analyses of cerebral cortex. *J Am Med Inform Assoc* 2001;8:443–459.
 22. DeLong MR. Primate models of movement disorders of basal ganglia origin. *Trends Neurosci* 1990;13:281–285.
 23. Hallett M, Obeso J. Where does chorea come from? Cortical excitability findings challenge classic pathophysiological concepts. *Mov Disord* 2015;30:169–170.
 24. Hawley JS, Weiner WJ. Hemiballismus: current concepts and review. *Parkinsonism Relat Disord* 2012;18:125–129.
 25. Oh SH, Lee KY, Im JH, Lee MS. Chorea associated with non-ketotic hyperglycemia and hyperintensity basal ganglia lesion on T1-weighted brain MRI study. *J Neurol Sci* 2002;200:57–62.
 26. Aylward EH, Liu D, Nopoulos PC, et al. Striatal volume contributes to the prediction of onset of Huntington disease in incident cases. *Biol Psychiatry* 2012;71:822–828.
 27. Burns LH, Pakzaban P, Deacon TW, et al. Selective putaminal excitotoxic lesions in non-human primates model the movement disorder of Huntington disease. *Neuroscience* 1995;64:1007–1017.
 28. Wong DF, Harris JC, Naidu S, et al. Dopamine transporters are markedly reduced in Lesch-Nyhan disease in vivo. *Proc Natl Acad Sci USA* 1996;93:5539–5543.
 29. King AD, Walshe JM, Kendall BE, et al. Cranial MR imaging in Wilson's disease. *AJR Am J Roentgenol* 1996;167:1579–1584.
 30. Brooks DJ, Ibanez V, Playford ED, et al. Presynaptic and postsynaptic striatal dopaminergic function in neuroacanthocytosis: a positron emission tomographic study. *Ann Neurol* 1991;30:166–171.
 31. Ząbek M, Sobstyl M, Dzierżęcki S, et al. Right hemichorea treated successfully by surgical removal of a left putaminal cavernous angioma. *Clin Neurol Neurosurg* 2013;115:844–846.
 32. Lehéricy S, Vidailhet M, Dormont D, et al. Striatopallidal and thalamic dystonia: a magnetic resonance imaging anatomoclinical study. *Arch Neurol* 1996;53:241–250.
 33. Alexander GE, DeLong MR, Strick PL. Parallel organization of functionally segregated circuits linking basal ganglia and cortex. *Annu Rev Neurosci* 1986;9:357–381.
 34. Lehéricy S, Ducros M, Van de Moortele PF, et al. Diffusion tensor fiber tracking shows distinct corticostriatal circuits in humans. *Ann Neurol* 2004;55:522–529.
 35. Di Martino A, Scheres A, Margulies DS, et al. Functional connectivity of human striatum: a resting state FMRI study. *Cereb Cortex* 2008;18:2735–2747.
 36. Fox MD, Buckner RL, Liu H, et al. Resting-state networks link invasive and noninvasive brain stimulation across diverse psychiatric and neurological diseases. *Proc Natl Acad Sci USA* 2014;111:E4367–E4375.
 37. Brusa L, Versace V, Koch G, et al. Improvement of choreic movements by 1 Hz repetitive transcranial magnetic stimulation in Huntington's disease patients. *Ann Neurol* 2005;58:655–656.

MACRA Changes How Neurologists Are Paid

What Is MACRA, and Why Is It Necessary?

The **Medicare Access and CHIP Reauthorization Act of 2015—MACRA**—replaced the Medicare Sustainable Growth Rate formula for calculating physician payments. The rapidly rising costs of health care in the US are unsustainable. Changes in the health care system are essential and must happen now.

How Will MACRA Affect Physician Payment?

Our health care system is moving from “fee-for-service” payments to a wider array of “value-based” payment models that put the patient at the center of care by calling for the improvement of the quality, safety, and overall experience of patient care while demonstrating cost-effectiveness by providing care that is less expensive and delivers similar or improved clinical outcomes.

Learn more at AAN.com/view/MACRA.

Neurology[®]

Network localization of hemichorea-hemiballismus

Simon Laganiere, Aaron D. Boes and Michael D. Fox

Neurology 2016;86;2187-2195 Published Online before print May 11, 2016

DOI 10.1212/WNL.0000000000002741

This information is current as of May 11, 2016

Updated Information & Services	including high resolution figures, can be found at: http://www.neurology.org/content/86/23/2187.full.html
Supplementary Material	Supplementary material can be found at: http://www.neurology.org/content/suppl/2016/05/11/WNL.0000000000002741.DC1
References	This article cites 36 articles, 6 of which you can access for free at: http://www.neurology.org/content/86/23/2187.full.html##ref-list-1
Subspecialty Collections	This article, along with others on similar topics, appears in the following collection(s): All Movement Disorders http://www.neurology.org/cgi/collection/all_movement_disorders Chorea http://www.neurology.org/cgi/collection/chorea fMRI http://www.neurology.org/cgi/collection/fmri
Permissions & Licensing	Information about reproducing this article in parts (figures, tables) or in its entirety can be found online at: http://www.neurology.org/misc/about.xhtml#permissions
Reprints	Information about ordering reprints can be found online: http://www.neurology.org/misc/addir.xhtml#reprintsus

Neurology® is the official journal of the American Academy of Neurology. Published continuously since 1951, it is now a weekly with 48 issues per year. Copyright © 2016 American Academy of Neurology. All rights reserved. Print ISSN: 0028-3878. Online ISSN: 1526-632X.

